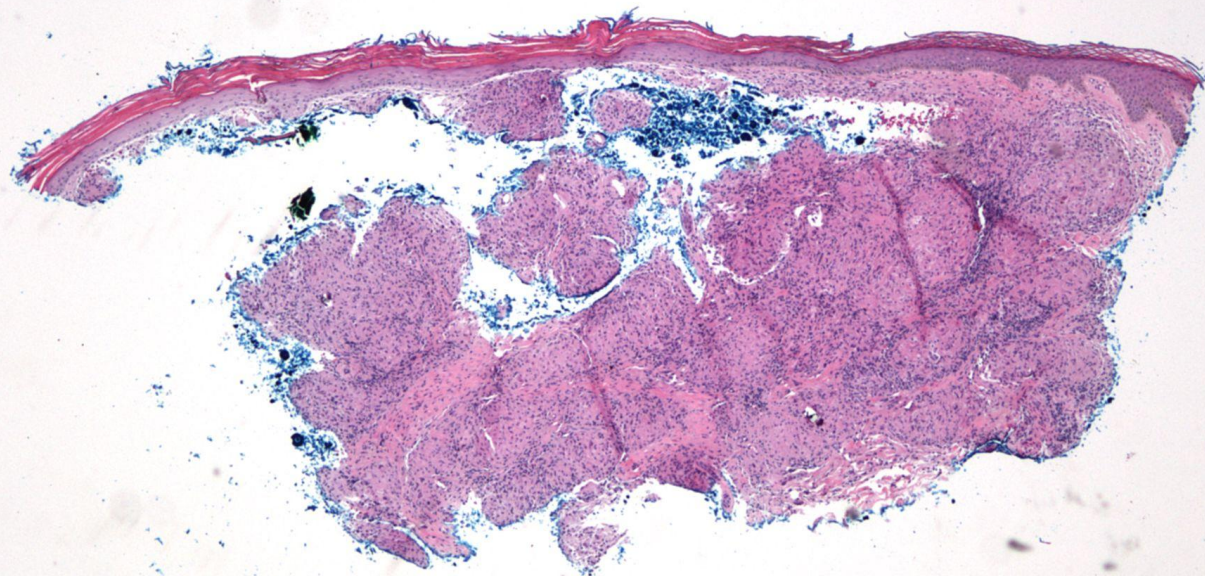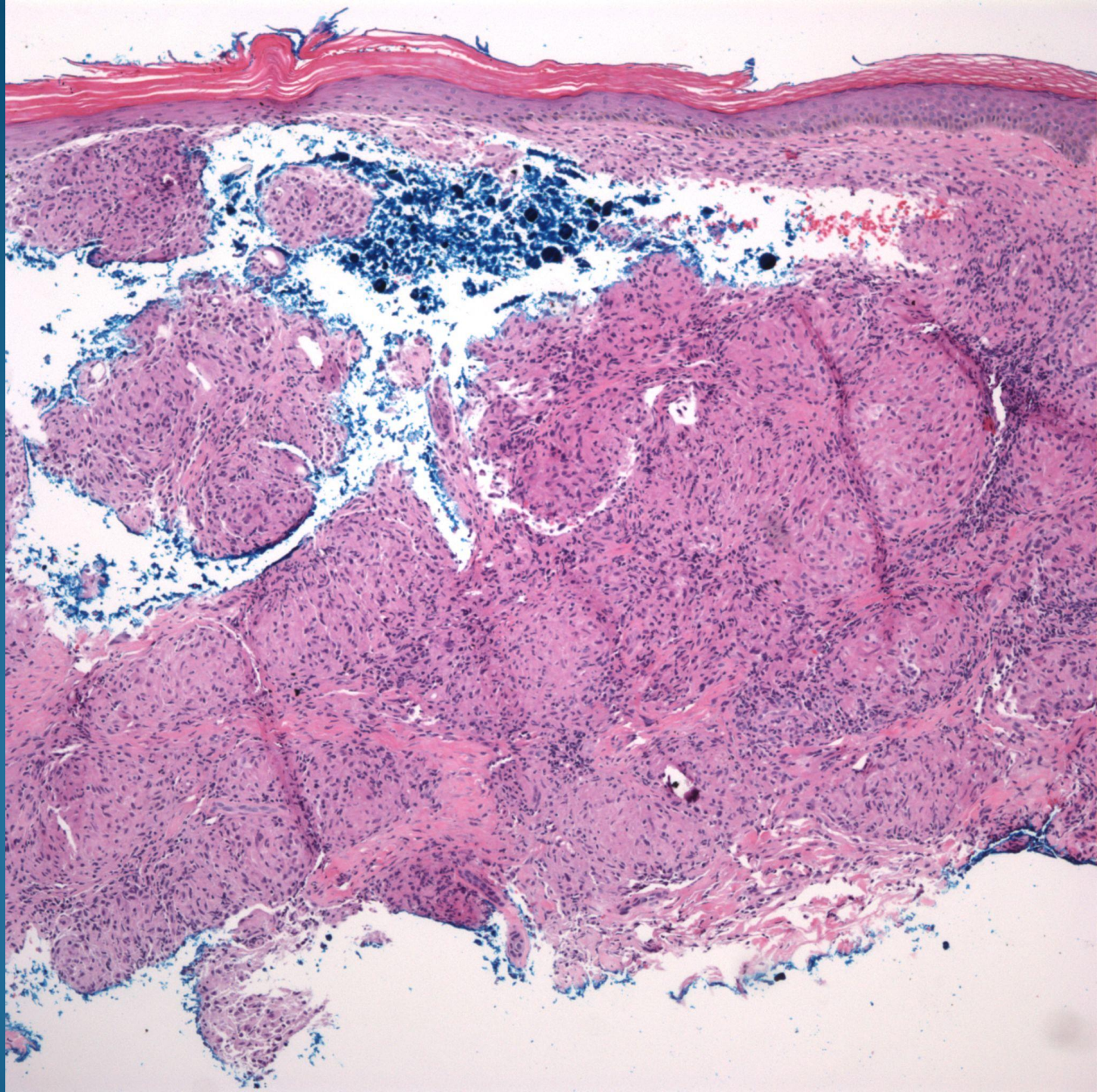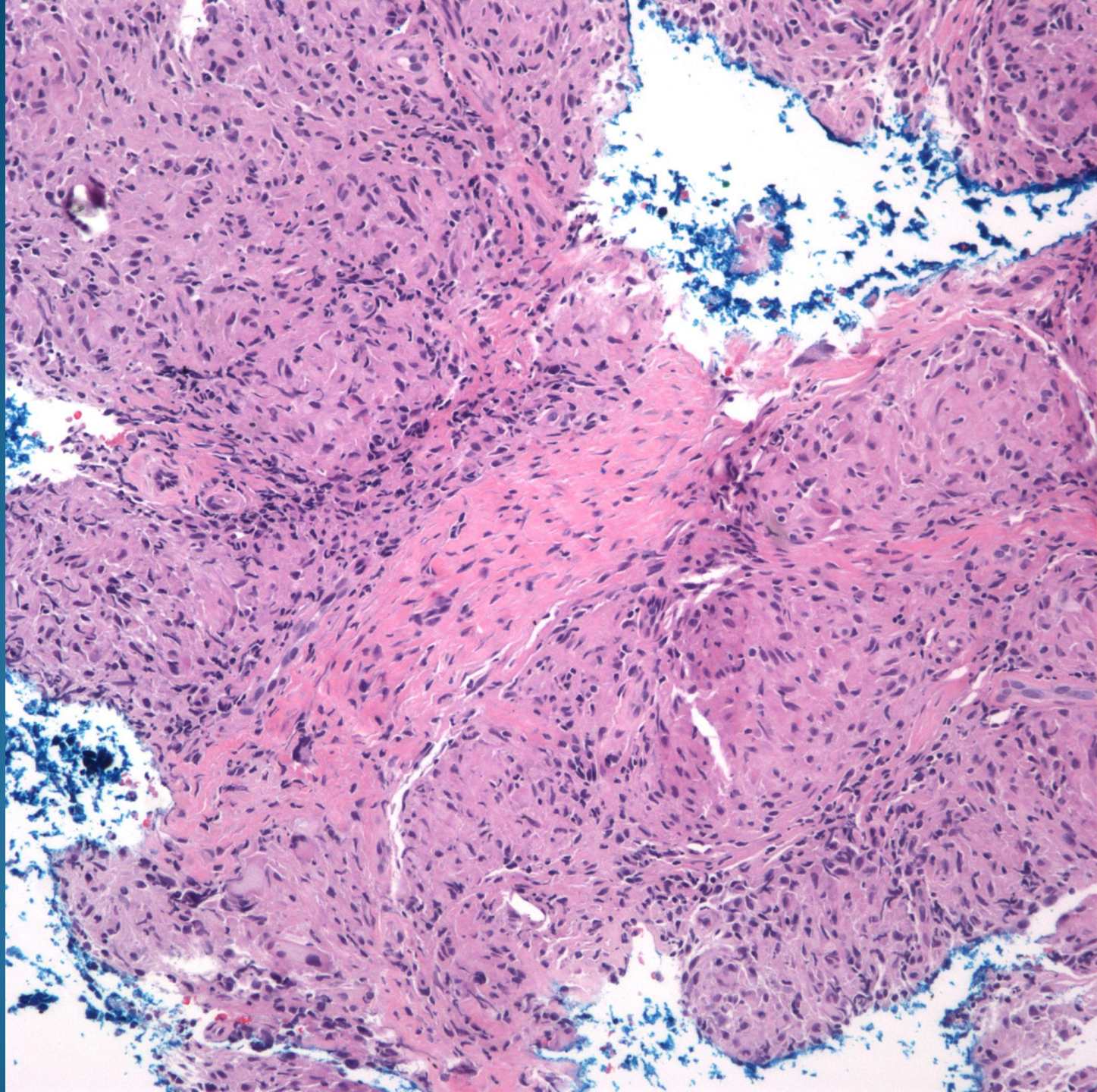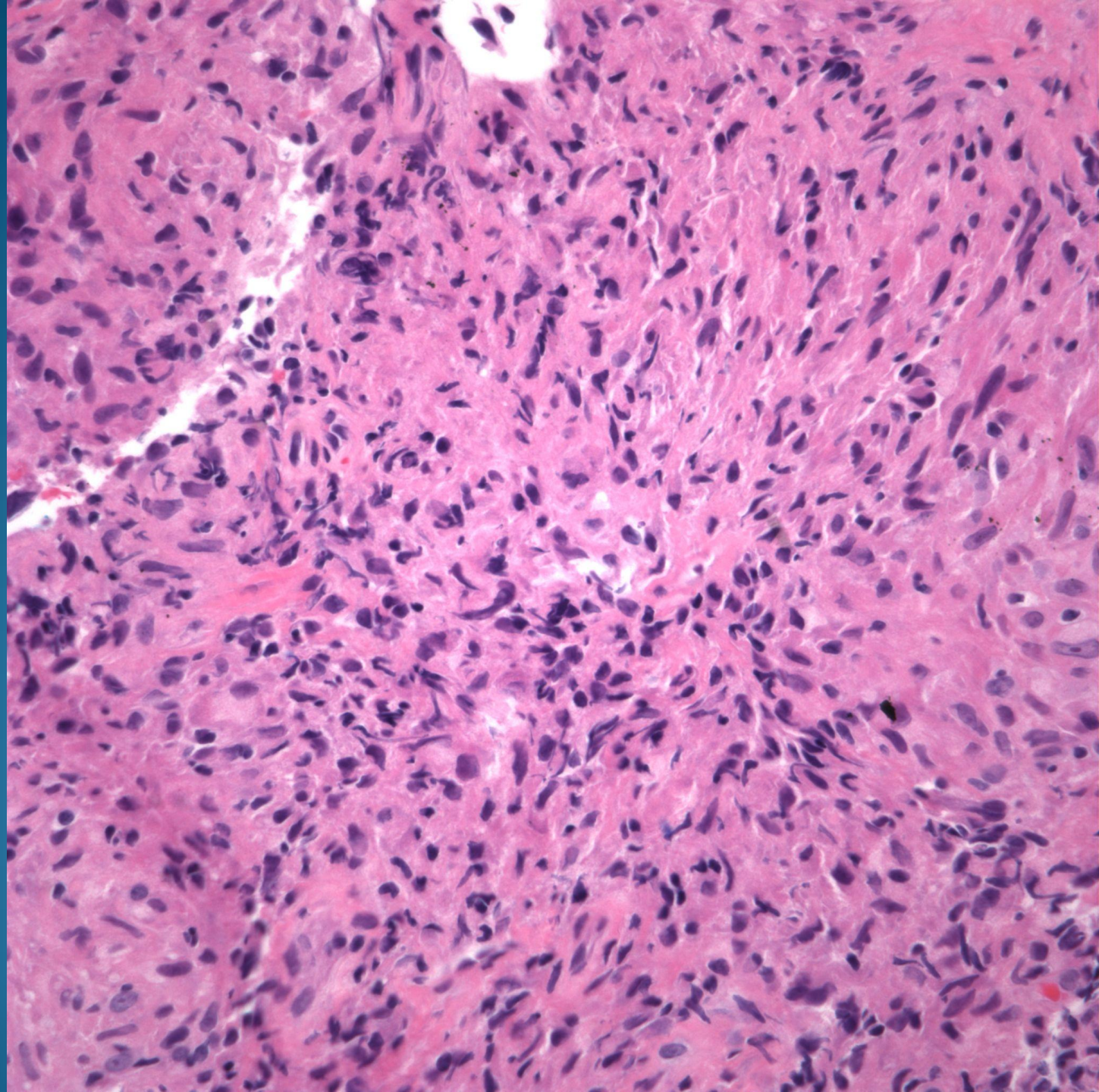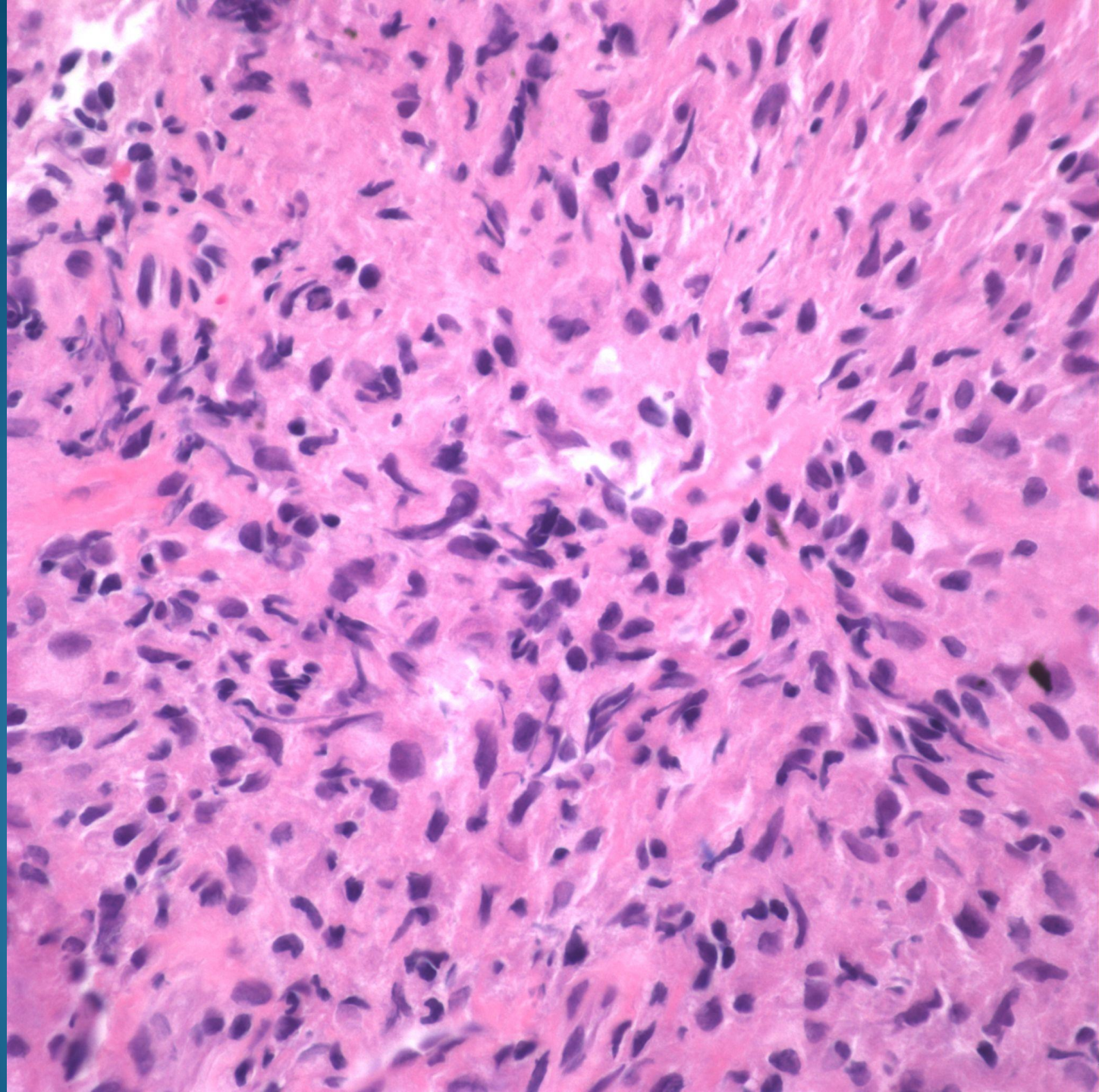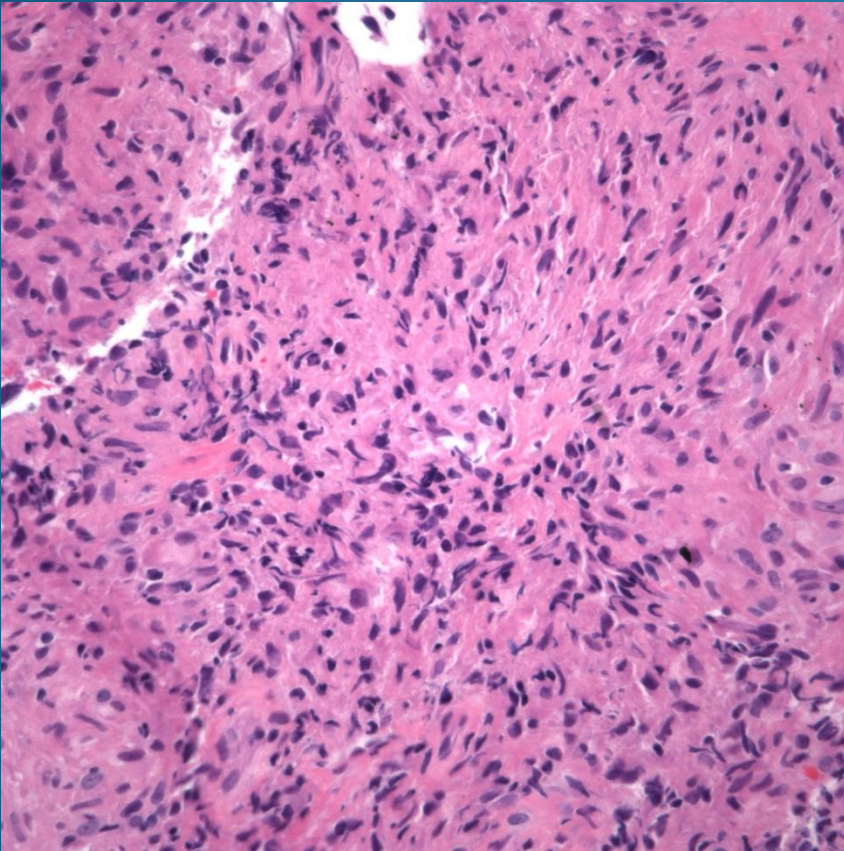


Sarcoidosis

Pearls



- Non-caseating granulomas with minimal inflammatory cell infiltrate (“naked granulomas”)
- Scattered giant cells
- Rare asteroid bodies
- Rule out foreign body
- Rule out infection